



PATIENT

Noodles Ricchio

SPECIES

Feline

BREED

DMH

SEX

Male Neutered

AGE

11 years

WEIGHT

18.7lbs

INTERPRETED BY

Maggie Machen Lamy,
DVM, DACVIM
(Cardiology)

IMAGING PERFORMED BY

Kim Liedberg

HOSPITAL NAME

SVS Imaging WI

REFERRING VET

Dr. Beyer

INVOICE

27603

DATE

11/21/22

PRESENTING CLINICAL SIGNS

History: Continues to lose weight. Coughing. Lungs sound busy. No murmur noted.

RADIOGRAPHIC FINDINGS *NOTE: Images submitted for supplemental cardiac information only.
Normal cardiac silhouette. No obvious evidence of CHF.

ELECTROCARDIOGRAPHIC FINDINGS *Note: Single lead ECGs are evaluated as a rhythm strip.
Morphology/MEA cannot be definitively commented on.

A single lead ECG is available; 25mm/s, 10mm/mV. The average heart rate is 188bpm with a regular rhythm. The rhythm is suspected to be sinus in origin, although p waves are difficult to visualize due to low voltage complexes. No ectopic beats, pauses or other dysrhythmias observed.

ECG diagnosis: Normal sinus tachycardia.

ECHOCARDIOGRAM FINDINGS

2D, m-mode, color flow and doppler imaging is available. The left ventricular wall is normal in dimension. There is a diffusely hyperechoic endocardium consistent with fibrosis. The papillary muscles are mildly remodeled and hyperechoic. The endocardium also appears remodeled. The left atrium is normal in size. The right atrium is normal in size. The right ventricle appears normal. The mitral valve is normal in structure and mobility. Blood flow through both the LVOT and RVOT is normal in velocity. Mild TR; normal velocity. No pleural or pericardial effusion seen. No obvious cardiac tumors.

CARDIAC CHART

FELINE CARDIAC PARAMETERS	BODY WEIGHT (kg)	HR (BPM)	IVSd (cm) <small>(Moise, Pipers)</small>	LVIDd (cm) <small>(Moise, Pipers)</small>	LVWd (cm) <small>(Moise, Pipers)</small>	FS (%)	EF (%)
NORMAL PARAMETER	-----	150-240	0.35-0.55	<2 <small>(mean 1.5)</small>	3.5-0.55	35-67	80-100
PATIENT	8.5		0.42	1.2	0.41	60	92
FELINE CARDIAC PARAMETERS	LA/AO <small>(Boon)</small>	LA/AO HEART BASE (Swe) <small>(Abbott)</small>	LA 2D short axis Base view (cm) <small>(Abbott)</small>		LVOT VEL <small>(m/s)</small>	RVOT VEL <small>(m/s)</small>	E max <small>(m/s)</small>
NORMAL	<1.5	<1.3	<1.2		<1.6	<1.3	<0.9
PATIENT	NM	1.4	1.3		0.8	1.0	NM

**Note: All measurements based upon multi-modal images and methods. An average value is reported.
Adapted from June Boon, Veterinary Echocardiography, 1998
Abbott J & MacLean H JVIM 2006;20: 111-119, Moise et al. Am J Vet Res 47:1476, 1986. Pipers et al. Am J Vet Res 40:882, 1979.*

INTERPRETATION OF THE FINDINGS & FURTHER RECOMMENDATIONS

Overtly normal geriatric cardiac structure and function. The LV wall thickness is normal and there is no evidence of elevated left atrial pressure. There is mild remodeling and fibrosis of the left ventricular wall, which is likely a normal variant. Serial echocardiography will be necessary to determine progression. No additional issues are identified and the ECG shows a sinus tachycardia.

**PATIENT**

Noodles Ricchio

These findings would suggest a progressive cough is noncardiac in origin. Further respiratory/treatment is recommended. An empiric course of Azithromycin therapy is often a good starting point, in addition to a heartworm test.

SPECIES

Feline

Given these findings, no medications are indicated.

BREED

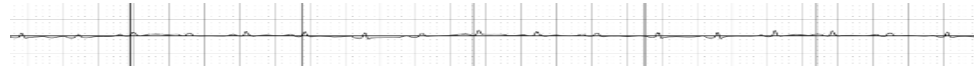
DMH

No cardiac contraindication for general anesthesia. Mild IV fluid restriction is advised. Risk for complication with steroid use typically follows LA dilation, which in this case is low. That being said, any cat can experience unexpected signs of intolerance and monitoring of RR/RE is advised particularly in the initiation phase.

SEX

Male Neutered

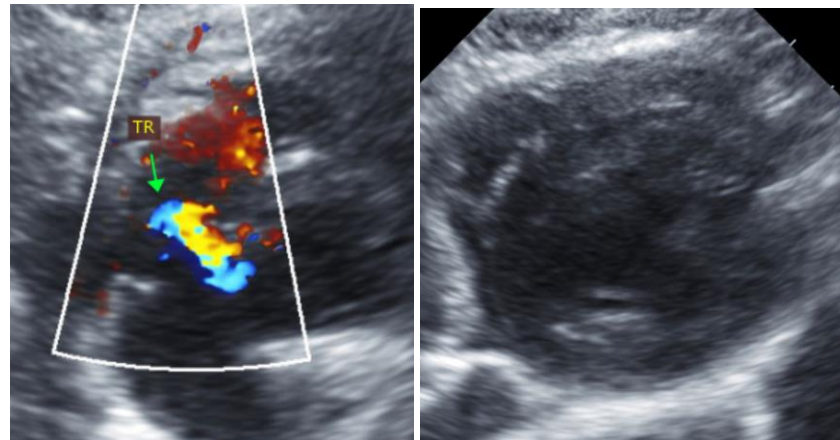
Recommend recheck echocardiogram in 1 year to screen for development of silent disease, sooner if a murmur/gallop is noted.

IMAGES**AGE**

11 years

WEIGHT

18.7lbs

**INTERPRETED BY**

Maggie Machen Lamy,
DVM, DACVIM
(Cardiology)

The information and recommendations provided are based on the images presented by the referring veterinarian. No evaluation can be communicated regarding pathology that was not visible in the image/video clips provided.

IMAGING PERFORMED BY

Kim Liedberg

Thank you for this referral. If the clinical or image interpretation does not parallel your findings or if I can be of any further assistance, please contact me.

HOSPITAL NAME

SVS Imaging WI

Maggie Machen Lamy, DVM
Diplomate of the American College of Veterinary Internal Medicine (Cardiology)
info@sonopath.com

REFERRING VET

Dr. Beyer

INVOICE

27603

DATE

11/21/22